

**PATIENT**

Lily Chatigny

**SPECIES**

Canine

**BREED**

Maltiese Mix

**SEX**

Female Spayed

**AGE**

11.1 years

**WEIGHT**

16.8lbs

**INTERPRETED BY**

Maggie Machen Lamy,  
DVM, DACVIM  
(Cardiology)

**IMAGING PERFORMED BY**

Loetitia Saint-Jacques,  
LVT

**HOSPITAL NAME**

Four Paws Animal  
Clinic

**REFERRING VET**

Dr. Lester

**INVOICE**

47655

**DATE**

4/22/26

**PRESENTING CLINICAL SIGNS**

History: Recent persistent cough, originally tx for Kennel cough (had just been picked up from being boarded), "voice change." 4.10.25 (heart murmur III/VI). 4.18.25 (heart murmur III/VI). 4.6.26 (heart murmur IV/VI), poss kennel cough, tx with metronidazole and cough tabs. 4.14.26: (IV/VI systolic murmur). Harsh lung sound bilaterally. Refill cough tabs. Films taken. Gave 6.25mg furosemide then radcon sent out and no further furosemide to be given, pimobendan 2.5mg BID. Radcon: Mild bronchitis, Left cardiomegaly, moderate left parenchymal bronchial narrowing secondary to left atrial compression +/- chondromalacia. 4.17.26: Added 1.5mL Hydrocodone and Homatropine 5mg and 1.5 mg/5 mL Oral Sol. BID. 4.22.26: (IV/VI murmur), no lung harshness, HR 130bpm. Since adding cough syrup and discontinuing furosemide - longer episodes of coughing have been lessened and "voice" is returning to normal.

-CXR report: showed lower airway disease. Cardiomegaly.  
-Abnormal PE/Chem/CBC/UA Results (4.15.26): Platelets 431, Na: K Ratio 27, ProBNP 4,589.

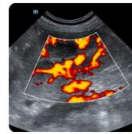
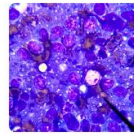
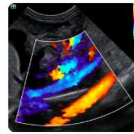
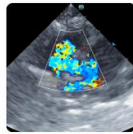
**ECHOCARDIOGRAM FINDINGS**

2D, m-mode, color flow and doppler imaging is available. Diffuse thickening of mitral valve leaflets with prolapse into the left atrial lumen. Marked eccentric mitral regurgitation with marked left atrial dilation. LV dilation with hyperdynamic myocardial function. The tricuspid valve appears mildly thickened with mild tricuspid regurgitation. TR velocity is mildly elevated. Right heart is mildly dilated. The pulmonic and aortic valves are normal in morphology and mobility. Normal pulmonic and aortic outflow velocities. No aortic or pulmonic insufficiency. No pericardial or pleural effusion noted. No obvious cardiac tumors observed.

**CARDIAC CHART**

<b>CANINE CARDIAC PARAMETERS</b>	<b>MR VMAX</b> (m/s)	<b>TR VMAX</b> (m/s)	<b>LA/AO</b> (Boon method)	<b>LA/AO</b> (Heart Base; Swe)	<b>FS</b> (%)	<b>EF</b> (%)	<b>EPSS</b> (cm)
<b>NORMAL PARAMETER</b>	4.5-5.5	<2.7	1.3	<1.6	28-40	40-100	<0.6
<b>PATIENT</b>	5.4	3.5	NM	2.5	47	79	0.3
<b>CANINE CARDIAC PARAMETERS</b>	<b>HR</b> (BPM)	<b>AV VMAX</b> (m/s)/	<b>PV MAX</b> (m/s)	<b>BODY WEIGHT</b> (kg)	<b>LA</b> 2D short axis Base view (cm)	<b>LVIDd</b> Avg; 2D and m-mode short axis (cm)	<b>LVIDs</b> Avg; 2D and m-mode short axis (cm)
<b>NORMAL PARAMETER</b>	50-100	0.7-1.7	0.7-1.6	BELOW	BELOW	BELOW	BELOW
<b>PATIENT</b>	150	1.2	1.1	7.6	3.7	4.1	2.2
*Normal chamber parameters expressed as a mean value (SD)				3	1.27 (5.3)	2.46 (2.46)	1.36 (5.5)
<b>BODY WEIGHT DEPENDENT PARAMETERS</b>				5	1.40 (4.5)	2.74 (5.2)	1.60 (4.7)
*Note: All measurements based upon multi-modal images and methods. An average value is reported.				10	1.50 (3.8)	3.27 (3.5)	2.06 (3.1)
				15	1.83 (2.0)	3.71 (2.4)	2.43 (2.1)
				20	2.02 (1.9)	4.14 (2.2)	2.80 (2.0)
				25	2.18 (2.4)	4.48 (2.9)	3.10 (2.5)
				30	2.33 (3.3)	4.83 (3.9)	3.39 (3.4)
				35	2.48 (4.3)	5.17 (5.0)	3.69 (4.5)
				40	2.62 (5.2)	5.48 (6.1)	3.96 (5.4)
				50	2.88 (7.1)	6.07 (8.3)	4.46 (7.4)

Adapted from June Boon, Veterinary Echocardiography, 1998  
Rishniw M and Hollis NE, J Vet Intern Med 2000; 14:429-435  
Hansson et al, Vet Rad and Ultrasound 2002  
Bonagura et al. Echocardiography: principles of interpretation, Vet Clin North Am 15:1177, 1995



**PATIENT**

Lily Chatigny

**SPECIES**

Canine

**BREED**

Maltiese Mix

**SEX**

Female Spayed

**AGE**

11.1 years

**WEIGHT**

16.8lbs

**INTERPRETED BY**

Maggie Machen Lamy,  
DVM, DACVIM  
(Cardiology)

**IMAGING  
PERFORMED BY**

Loetitia Saint-Jacques,  
LVT

**HOSPITAL NAME**

Four Paws Animal  
Clinic

**REFERRING VET**

Dr. Lester

**INVOICE**

47655

**DATE**

4/22/26

**INTERPRETATION OF THE FINDINGS & FURTHER RECOMMENDATIONS**

The murmur is due to chronic degenerative valve disease causing marked mitral and mild tricuspid regurgitation. Marked left atrial and ventricular enlargement indicate the risk for spontaneous congestive heart failure is elevated. Mild pulmonary hypertension is noted, which is likely secondary to a reported cough and elevated LA pressure. No obvious additional issues are noted.

A cough in this patient with severe heart disease is likely multi-factorial in origin, including mainstem bronchi compression and/or potentially some degree of upper or lower airway disease. Early CHF/pulmonary edema should also be considered; however, this is less likely based upon the CXR results as well as a reported cough in the absence of labored breathing.

Recommend institute cardiac supportive medications including a weak diuretic (spironolactone) for potential survival benefit and advise close monitoring at home for need for Lasix therapy. Cough suppression (up to q4-6 hours) may also be helpful for any component of a mechanical cough. **Monitoring of sleeping breathing rates is recommended as the best way to screen for CHF at home.**

Omega fatty acid supplementation and mild salt restriction may also be of some long-term benefit. Monitor for development of a worsening cough, labored breathing, exercise intolerance or collapse episodes. Long term prognosis is guarded to poor with stage (late) B2 disease, with risk for CHF in the near future. Once diagnosed, the average survival time for canine patients is 8-9 months on medications; however, most are able to maintain a good quality of life for that period. Patient will always be at risk for progression to CHF, development of arrhythmias/LA tear, syncope and/or sudden death in the future.

**Elective anesthesia is not advised, as there is high risk for complication.**

**PLAN**

Baseline BP recommended. Institute Pimobendan 0.3mg/kg PO q12h. Institute Spironolactone 1-2mg/kg PO q12h. If BP > 130mmHg, institute ACE-I (benazepril or enalapril) 0.5mg/kg PO q12h. Consider hydrocodone with homatropine for QOL (0.2-0.4mg/kg PO up to q4-6 hours PRN for cough; available in 5/1.5mg tabs and 5mg/5ml liquid suspension).

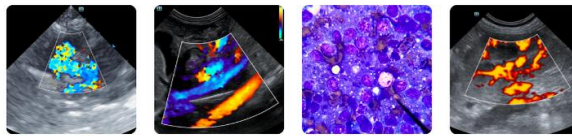
A renal panel and BP are recommended in 1-2 weeks, then every 3-4 months lifelong to ensure tolerance of medications.

A recheck echocardiogram is recommended in 6 months to screen for progression, sooner if clinical signs arise in the interim.

Imaging  
performed by



Four Paws Animal Wellness Sonography, Inc.  
pawsonography@gmail.com  
530-786-8340



**Clinical Sonography & Telemetry**  
Educational Teleconsultation Services™

**SonoPath**

FOSTERING THE ART OF VETERINARY MEDICINE™

SonoPath.com info@sonopath.com 1.800.838.4268

## PATIENT

Lily Chatigny

## SPECIES

Canine

## BREED

Maltiese Mix

## SEX

Female Spayed

## AGE

11.1 years

## WEIGHT

16.8lbs

## INTERPRETED BY

Maggie Machen Lamy,  
DVM, DACVIM  
(Cardiology)

## IMAGING PERFORMED BY

Loetitia Saint-Jacques,  
LVT

## HOSPITAL NAME

Four Paws Animal  
Clinic

## REFERRING VET

Dr. Lester

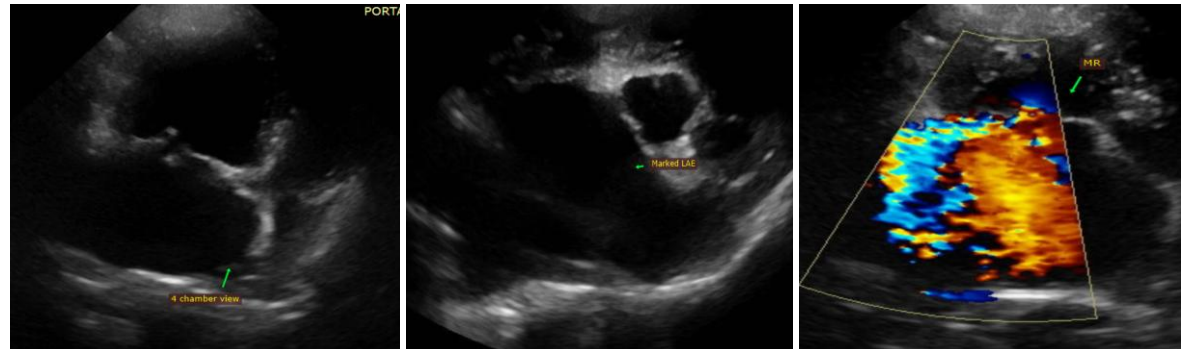
## INVOICE

47655

## DATE

4/22/26

## IMAGES



**The information and recommendations provided are based on the images presented by the referring veterinarian. No evaluation can be communicated regarding pathology that was not visible in the image/video clips provided.**

Thank you for this referral. This report was generated using transcription software, and minor dictation errors may be present. If the clinical or image interpretation does not parallel your findings or if I can be of any further assistance, please contact me.

**Maggie Machen Lamy, DVM**

**Diplomate of the American College of Veterinary Internal Medicine (Cardiology)**

info@sonopath.com